

## FASCIA ILIACA COMPARTMENT BLOCK

Document Type: Clinical Guideline  
Clinical Lead: Dr MK Varma  
Author/s: Dr MK Varma  
Directorate: Perioperative and Critical Care  
Approved by Sub Committee/Group:

Date Approved by Sub Committee/Group:  
Date Approved by Clinical Guidelines Group:  
Date of Issue:  
Review Date: (3 years max)  
Version:

**This document is a description of the technique and is not intended to replace training. Before you attempt this procedure please ensure that you have been adequately trained.**

The fascia iliaca compartment block (FICB) is a useful technique for pre- and post- operative analgesia used in hip fractures and proximal femur fractures. Its use means patients require less opiate analgesia and therefore do not suffer their unwanted side effects.

It involves infiltration of the space containing the iliopsoas muscles with a large volume of local anaesthetic. The nerves travelling in this space are the femoral nerve, the lateral cutaneous nerve of thigh and obturator emerging from the lumbar plexus.

This block can be performed with a suprainguinal or infrainguinal approach and can be used as a single shot block or include the insertion of a nerve catheter.

The choice of approach and the decision regarding single block versus nerve catheter should be based on operator experience and patient specific factors including coagulation status.

The document below describes the anatomy and technique of performing the suprainguinal approach to the fascia iliaca block and the insertion of a fascia iliaca nerve catheter via this approach for perioperative care of patients with hip and proximal femur fractures.

The infrainguinal single-shot fascia iliaca approach is not described in detail in this document, however, this is an entirely appropriate approach to provide single shot analgesia in this patient group.

The block is typically performed by a trained member of anaesthetic staff with a trained assistant in the block area in recovery on level 5, level 3, or in an anaesthetic room and should comply with AAGBI monitoring, theatre checklists and 'stop before you block' safety initiatives.

## Anatomy

Knowledge of the anatomy of the femoral triangle is essential for both the suprainguinal and infrainguinal approach to the fascia iliaca block. Figure 1 illustrates the cross sectional anatomy of the left thigh. Anatomical knowledge of the suprainguinal structures and sonoanatomy is also required for successful and safe suprainguinal fascia iliaca block.

During the infrainguinal approach to the fascia iliaca block local anaesthetic solution is placed just deep to the fascia iliaca avoiding close proximity to the femoral nerve, allowing a safe block with medial spread throughout the fascia iliaca compartment. This is a compartment block that requires a large volume of up to 40ml of a suitable and safe strength local anaesthetic to be effective.

The suprainguinal block requires similar spread of local anaesthetic in the fascia iliac compartment however the approach and sonoanatomy are different to the infra inguinal approach. The important landmarks are the anterior superior iliac spine (ASIS) and the anterior inferior iliac spine (AIIS). The Sartorius and Internal Oblique muscles may also be visualized.

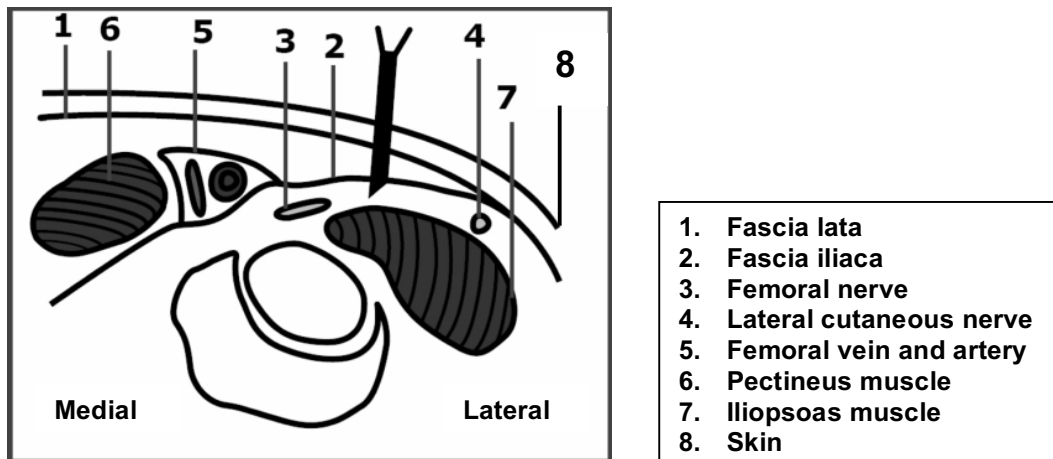
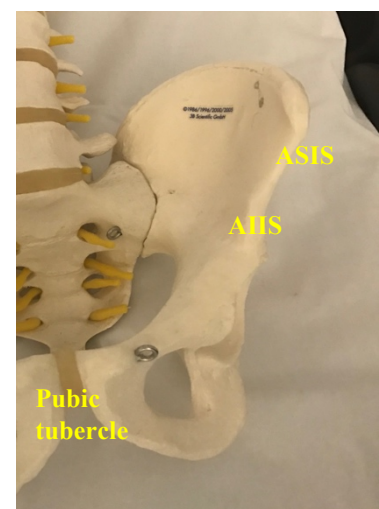
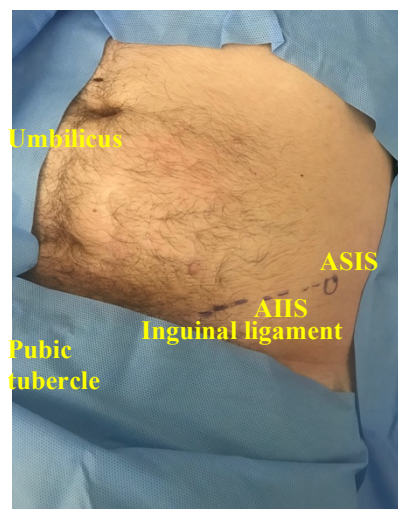


Fig 1. Cross sectional anatomy of the left thigh <sup>1</sup>

### Surface Anatomy of Supra inguinal approach to fascia iliaca block

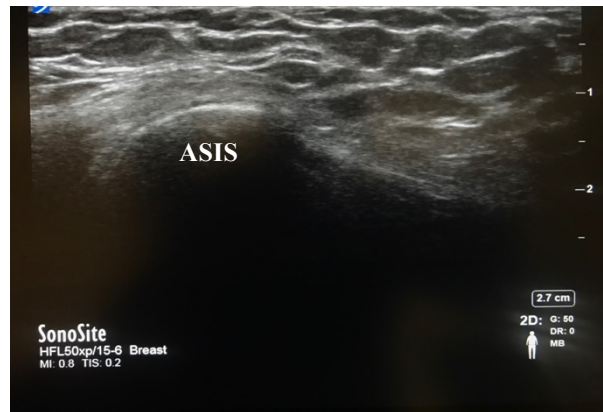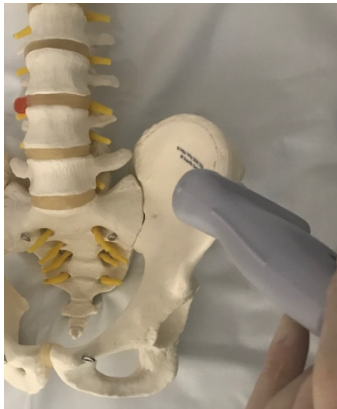The surface anatomy of the supra inguinal fascia iliaca block includes: The Anterior Superior Iliac Spine (ASIS); the pubic tubercle; the inguinal ligament and the umbilicus.

The adjacent pictures illustrate the surface anatomy and how this surface anatomy translates to the bony anatomy of the pelvis.

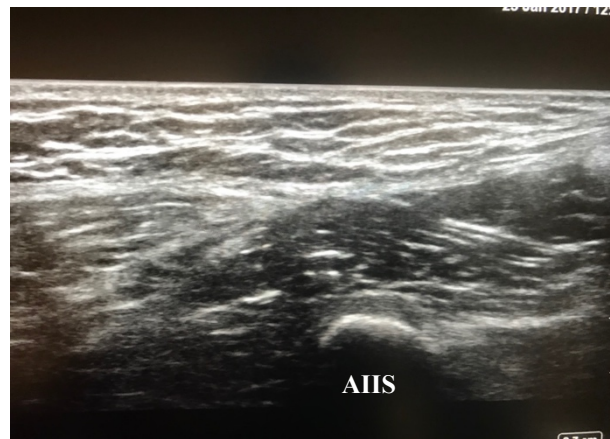
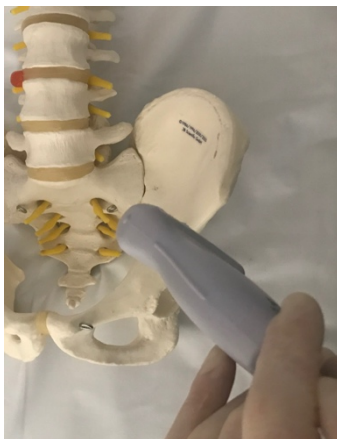
## Sonoanatomy of supra inguinal approach to fascia iliaca block

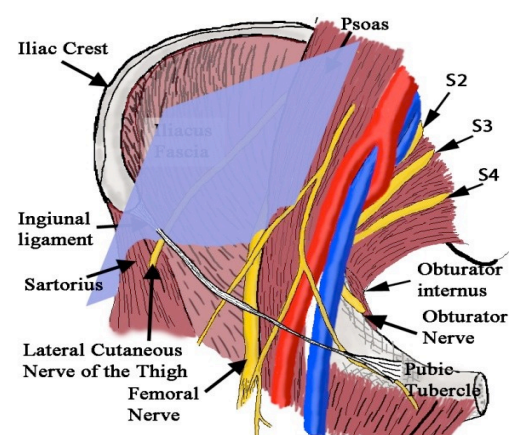
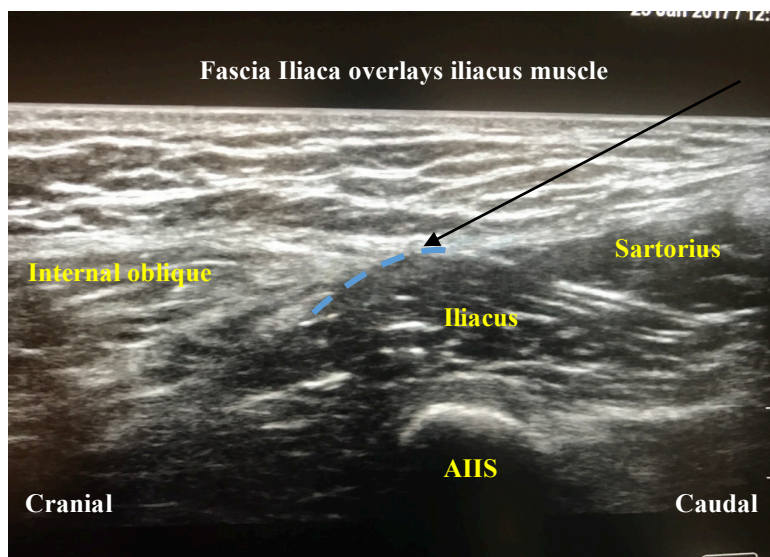
The Ultrasound probe position shows the orientation of the probe used to find the ASIS.



The probe is then moved medially and caudally to locate the Anterior Inferior Iliac Spine (AIIS) above which the iliacus muscle can be found covered superiorly by the fascia iliaca.

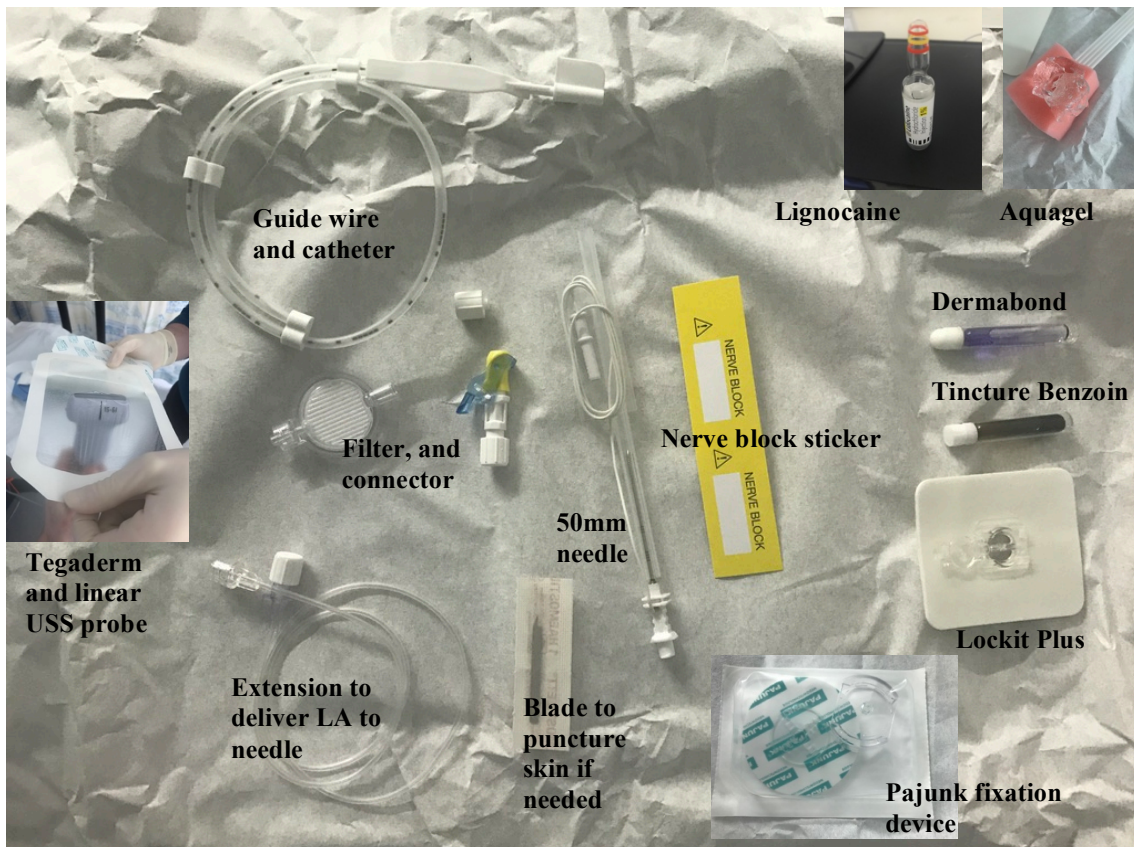
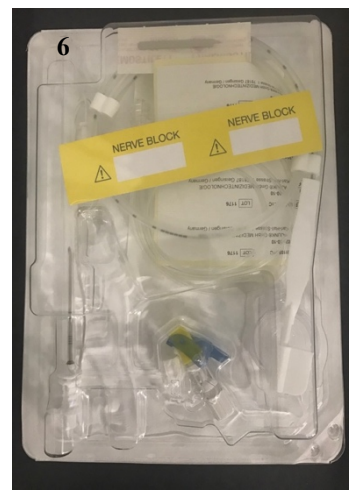
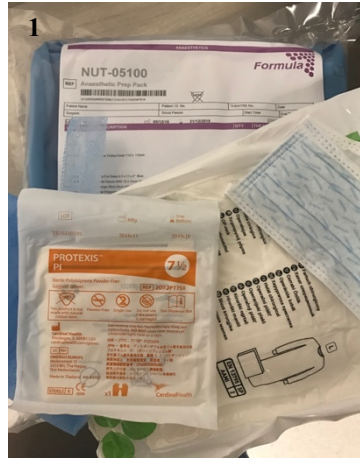

Key structures should be identified prior to performance of the block. These structures including the fascia iliaca (Blue dashed line) are highlighted in the picture below. The plane of the ultrasound beam should be perpendicular to the inguinal ligament, lateral to the femoral artery and nerve as illustrated in figure below. <sup>1</sup>



## Equipment required for Fascia Iliaca nerve catheter

1. Anaesthetic prep pack
2. Sterile gloves, gown, hat, mask
3. Chlorhexidine solution 0.5%
4. 0.25% levobupivacaine (chirocaine)
5. Normal saline if required
6. Pajunk Sono Echo nerve catheter set
7. Orange (25G) needle, 1% lidocaine
8. 2.5 ml and 4 x 10 ml syringes
9. Ultrasound Machine and linear probe
10. Tegaderm Ultrasound probe cover
11. Aquagel
12. Dermabond
13. Tincture Benzoin
14. Lockit plus- securement set
15. Adhesive dressing
16. Smith Nephew Grid dressing
17. Mefix



## **Procedure: Fascia Iliaca Nerve catheter supra inguinal approach**

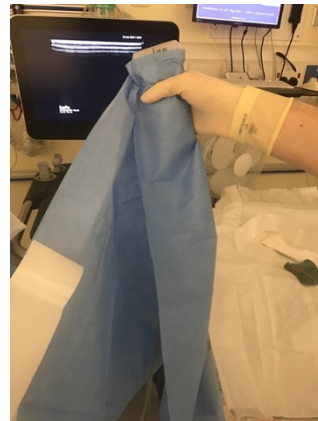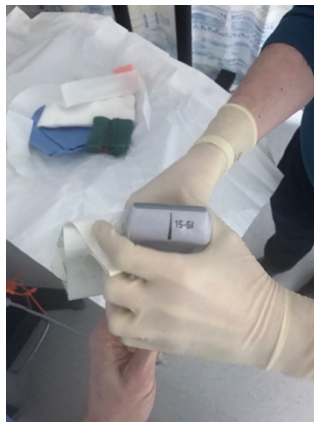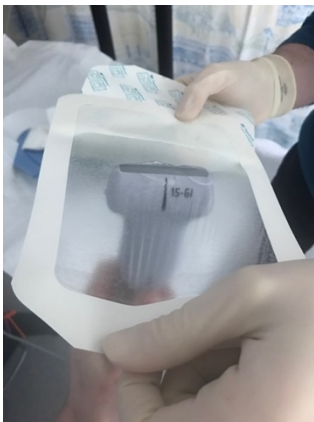1. Obtain written consent

Potential risks (very rare): failure, soft tissue infection, vascular puncture, viscus puncture, nerve damage, local anaesthetic toxicity

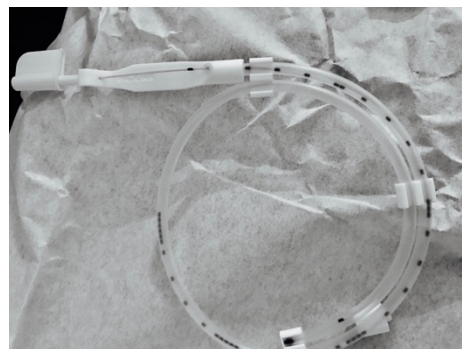
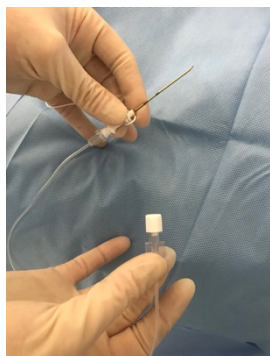
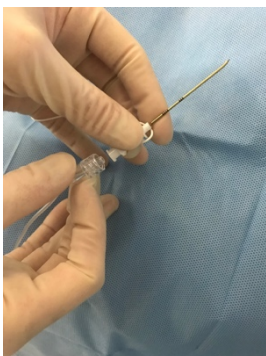
Cautions: anticoagulation

Contraindications: overlying skin infection, femoral vessel artificial grafts

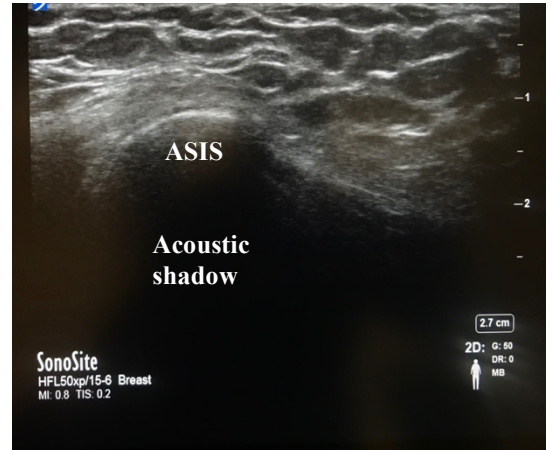
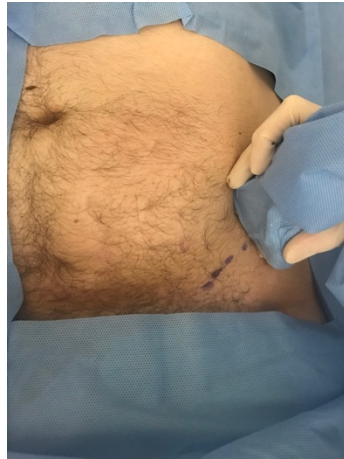
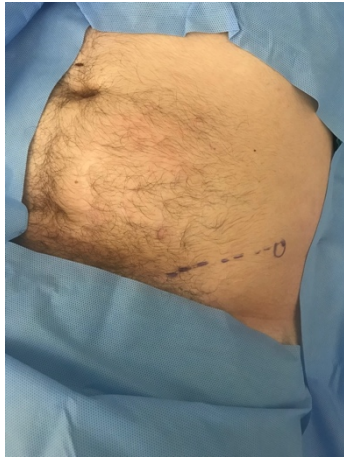
2. Ensure working intravenous access established
3. Standard monitoring (BP, SpO2, ECG) and trained assistant
4. Nerve catheter requires surgical scrub, gown, sterile gloves, mask and hat
5. Utilise anaesthetic prep pack, open the equipment required (see list above)
6. Clean the skin with 0.5% chlorhexidine
7. Drape the area of the groin/abdomen leaving surface anatomy visible.
8. Ask your assistant to pass you the linear Ultrasound probe pre-covered with Aquagel, apply a sterile Tegaderm to the ultrasound probe and cover trailing lead with sterile drape to maintain asepsis



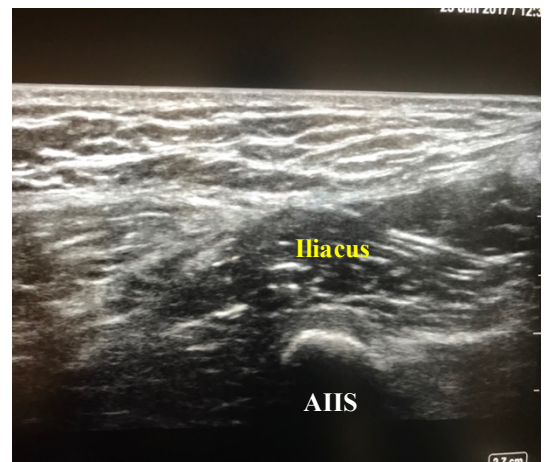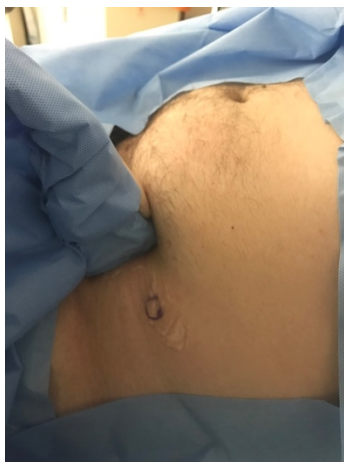
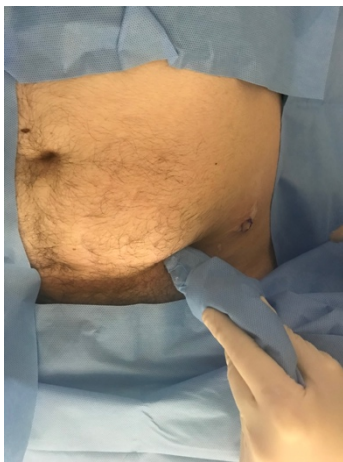9. Connect the 50 mm nerve catheter needle to the extension set and ask your assistant to flush through with either 0.25% levobupivacaine or normal saline if using hydro-dissection. Have nerve catheter to hand to allow ergonomic threading when required.



10. To commence the block, the linear probe is placed over the Anterior Superior Iliac Spine (ASIS), directed towards the umbilicus and perpendicular with the inguinal ligament. The sonoanatomy should reveal an acoustic shadow beyond the ASIS. If sonoanatomy is difficult confirmation of location may be aided by scanning medially to find the femoral artery, then laterally along inguinal ligament to find the ASIS.



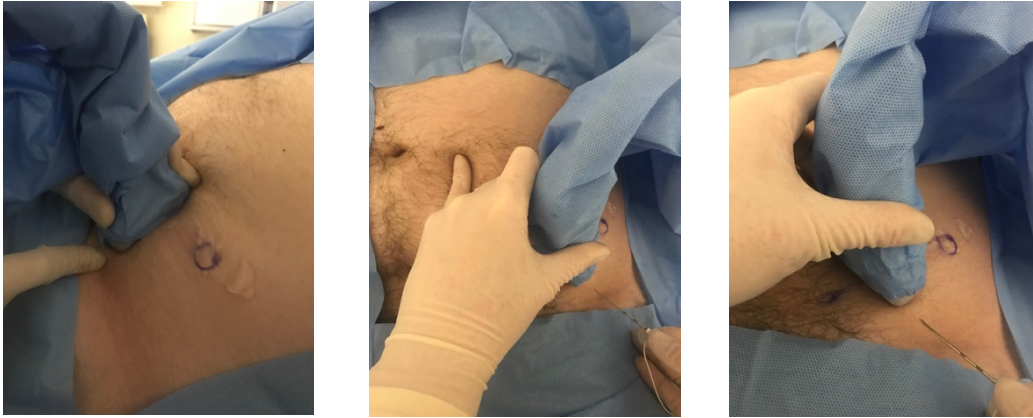11. The probe is then moved medially to locate the bone of the anterior inferior iliac spine (AIIS). This is seen deep under the muscle belly of the iliacus. The iliacus fascia is the fascial sheath covering iliacus muscle. The probe may be tilted to point into the pelvis (tilting the top of the probe more medially) to optimize the view or rotated toward the Xiphisternum (away from the umbilicus) more parallel with the midline.



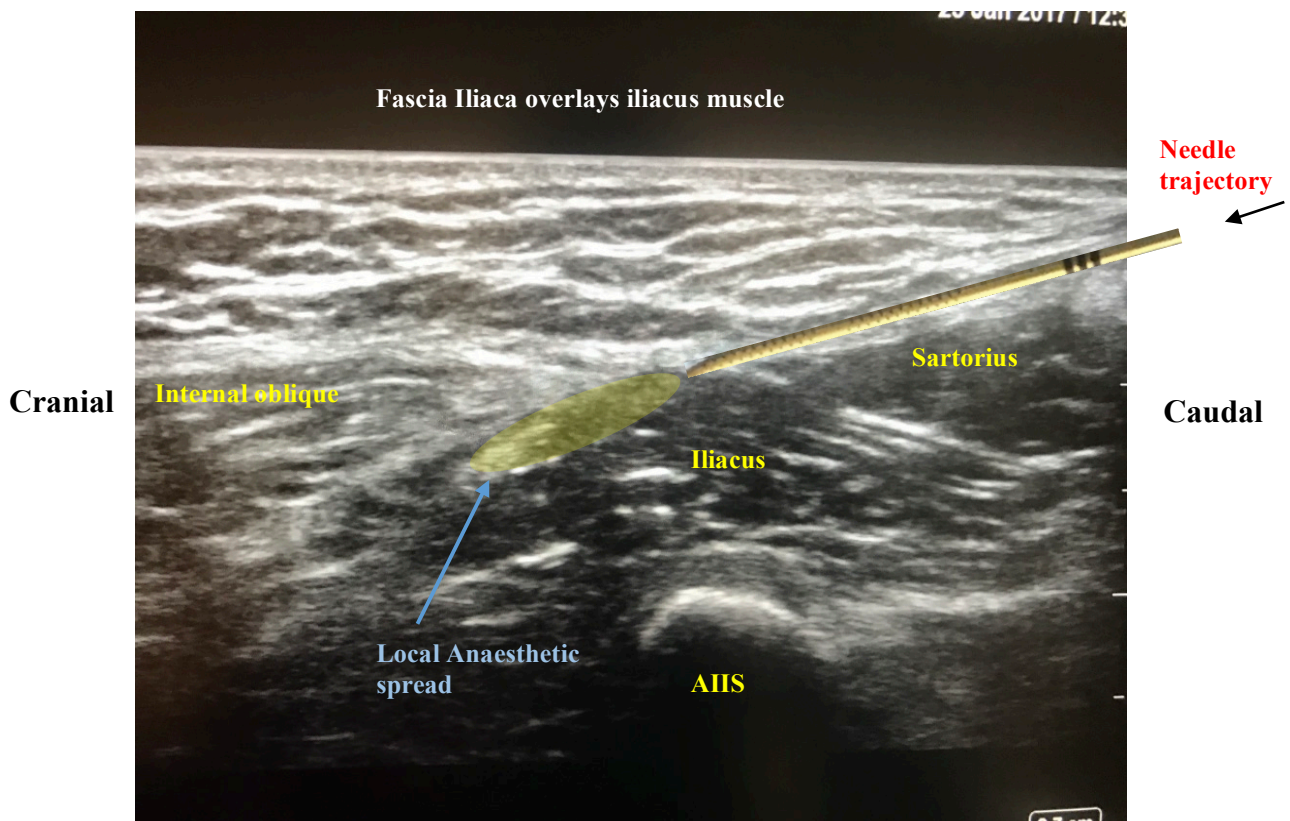
12. STOP BEFORE YOU BLOCK, check correct patient, correct site, correct side, indication and consent.

13. Infiltration of 2 ml of plain 1% lidocaine with 2.5ml syringe and orange needle once the puncture site is identified on ultrasound scanning.

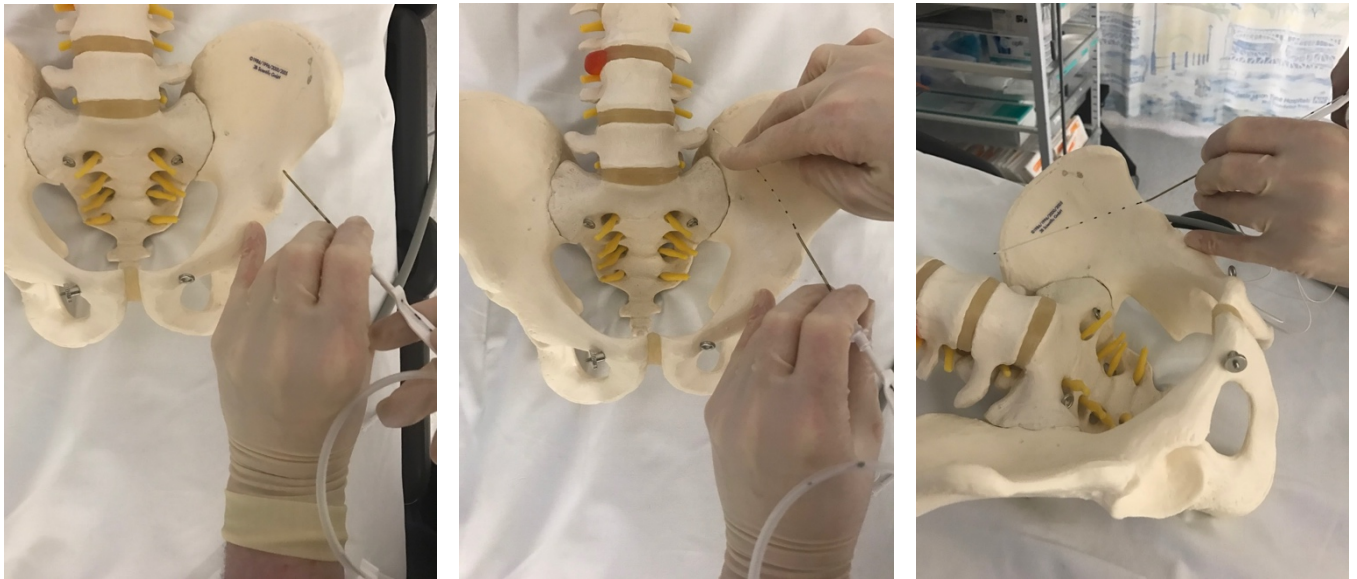
14. An in-plane approach is used, inserting the 50mm nerve catheter needle under direct ultrasound vision in a caudal to cranial direction as illustrated below, using hydrodissection as required ensuring the needle tip is visualized at all times. Colour Doppler can be used to visualize any blood vessels in the area if required.



15. Once the fascia iliaca is penetrated a small volume of fluid is injected under imaging. The fluid should spread between the iliacus muscle and the fascia iliaca to create a small lens. The needle is repositioned if this spread is not seen. Once the needle is about 1 to 2 cm past the AIIS the distending solution appears much less constrained by the fascia and runs well ahead of the needle into the pelvis. Once a good position is achieved 25-40 ml of local anaesthetic can be deposited at an appropriate volume and concentration for the patient's weight and age.



16. After injection of local anaesthetic to create space, whilst stabilizing the needle the extension set should be detached and the nerve catheter threaded. The catheter should thread easily and should be placed approximately 10cm beyond the depth of the needle tip leaving approximately 10 cm within the fascia iliaca compartment.



17. It may be possible to confirm correct placement of the catheter on ultrasound after placement however this may be difficult and may not be necessary. Remove the needle, leaving the catheter in place approximately 10 cm beyond the needle depth. An internal guidewire will also be removed at the same time as removing the needle.

18. Confirm that local anaesthetic can be injected down the nerve catheter by attaching the connector and filter to the nerve catheter. Deliver any additional local anaesthetic not given prior to catheter insertion.

19. Secure the nerve catheter to the skin away from the area of surgery so it can be used perioperatively
- Dry the skin
  - Apply dermabond to the entry point of the nerve catheter
  - Apply tinc-benz to the site around the catheter which will help stick the dressing to the skin
  - Stick the catheter down with the Lock-it plus device
  - Secure the filter to the skin with the Pajunk fixation device away from surgical site
  - Apply dressing over catheter and site

20. Document procedure on regional anaesthetic chart including the dose of anaesthetic given

21. Complete the nerve catheter prescription and the e-record fascia iliaca order set and RA database. Standard prescription would

NEWCASTLE UPON TYNE HOSPITALS NEB FOUNDATION TRUST ACUTE PAIN SERVICE, FREEMAN HOSPITAL				
ASSET ID				Alpha patient identification label in box below or complete details
Stimulating Catheter YES / NO		Tunnelled YES / NO		Date
Complications on insertion		Catheter mark at skin		Allergies
Needle depth				End point
NERVE CATHETER INSERTION PRESCRIPTION				
DATE	SITE	LOCAL ANAESTHETIC GIVEN THROUGH CATHETER AT INSERTION	SIGN + PRINT NAME	
NERVE CATHETER PRESCRIPTION				
INFUSION PRESCRIPTION				
SETTINGS				
DATE	TIME	DRUG (%)	INFUSION RATE (mls per hour)	SIGN + PRINT NAME



## Local Anaesthetic Dose and nerve catheter prescription

Local Anaesthetic Drug Volumes and Doses		
Body Weight	Maximum levobupivacaine Dose	Dose Calculation
< 50kg	2mg/kg bolus of 0.25% and an infusion of 0.125% at 6ml/hr	Body weight (Kg) x 0.8ml 0.25% levobupivacaine made up to 40mls with normal saline
≥ 50kg	100mg (40ml 0.25% levobupivacaine) and an infusion of 0.125% at 8ml/hr	

### Local anaesthetic toxicity

Ensure that you have read the Association of Anaesthetists of Great Britain & Ireland (AAGBI) guidelines on the management of local anaesthetic toxicity (available in Theatres and on intranet) and you know where the nearest bag of intralipid is located. Link to AAGBI guideline [https://www.aagbi.org/sites/default/files/la\\_toxicity\\_2010\\_0.pdf](https://www.aagbi.org/sites/default/files/la_toxicity_2010_0.pdf).

### Reference

1. Neuroaxiom.com

### Authors

**Dr T Cairns**  
ST7 Anaesthetic Trainee

**Dr M K Varma**  
Consultant

**Dr J Womack**  
Consultant

Perioperative and Critical Care  
RVI  
NUTH  
January 2017